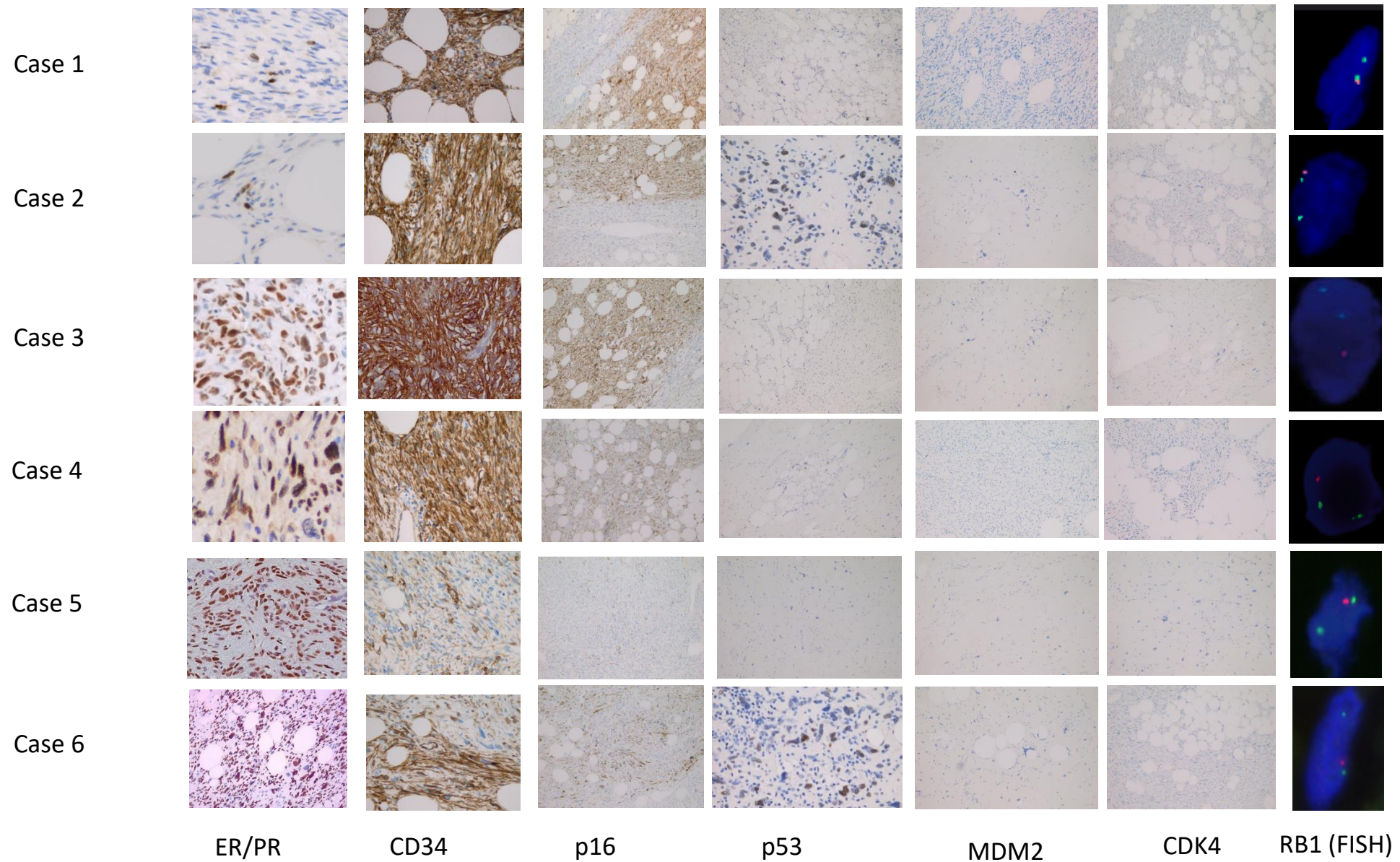
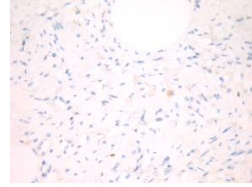
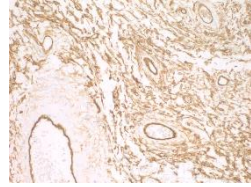
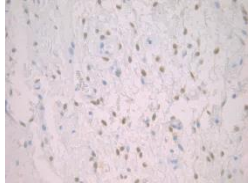


Figure S1: Immunohistochemical and fluorescence in situ hybridization(FISH) result of six cases of atypical angiofibroma/angiofibroma with sarcomatous transformation and two cellular angiofibroma control cases.



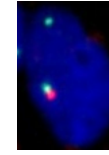
Control Case 1



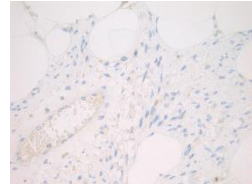
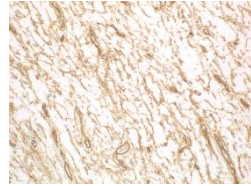
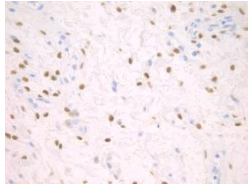
Not performed

Not performed

Not performed




Control Case 2



Not performed

Not performed

Not performed



ER/PR

CD34

p16

P53

MDM2

CDK4

RB1 (FISH)