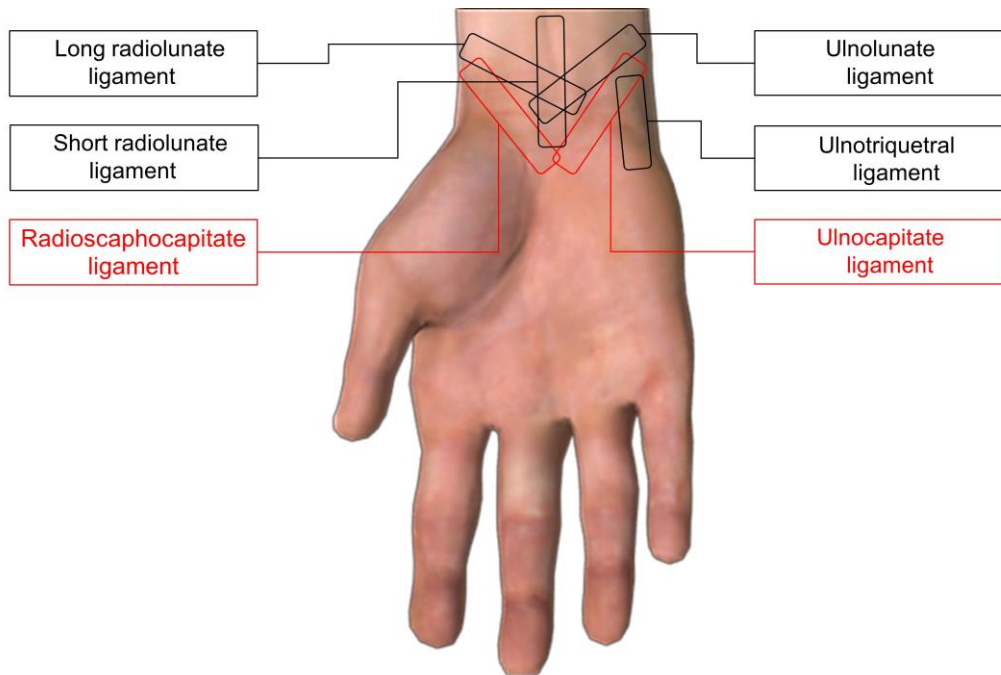
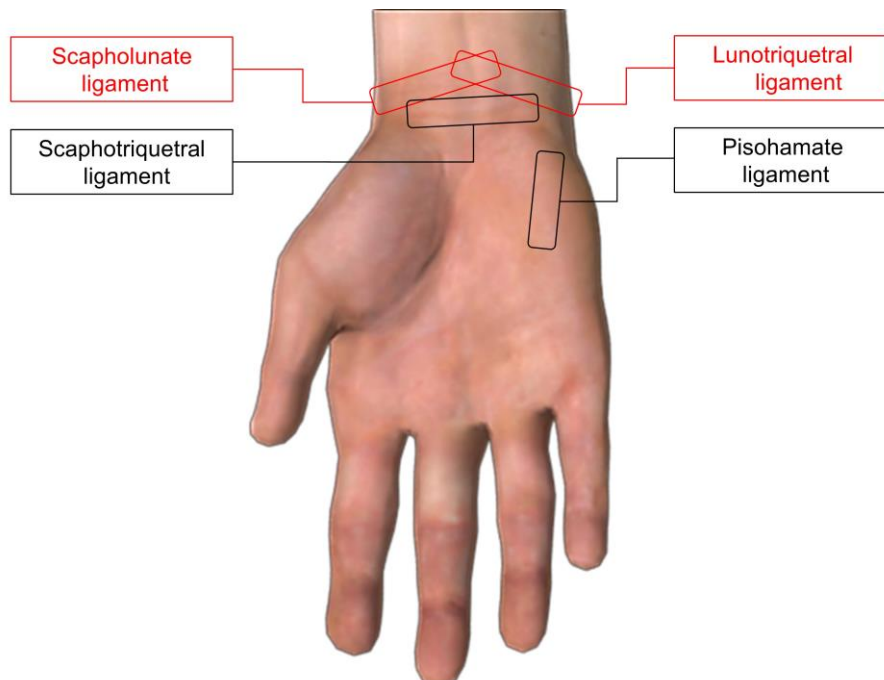


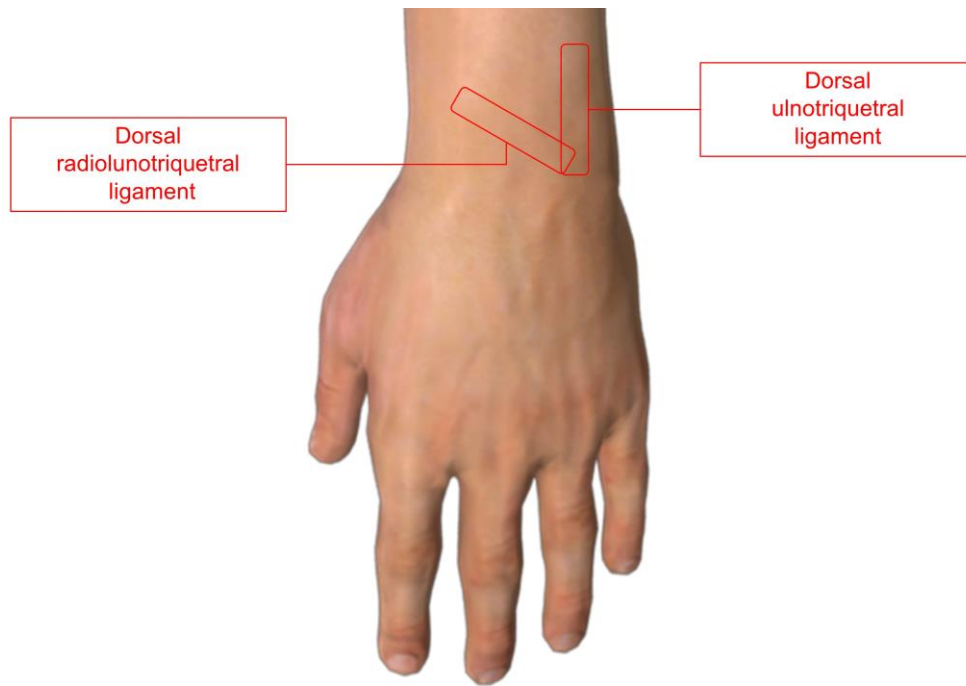
### Supplementary Figures



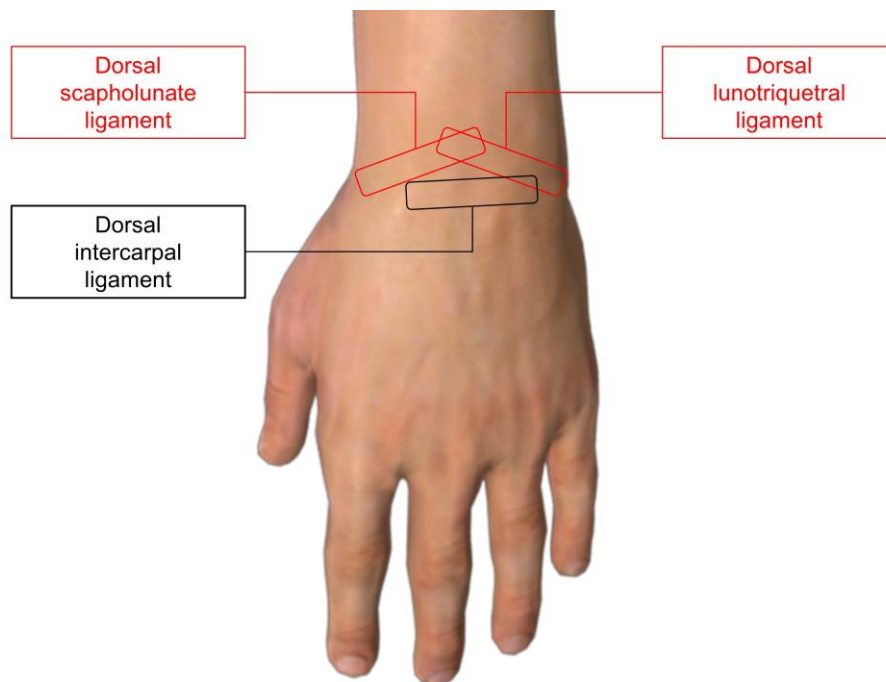
**Figure S1.** The position of the transducer for visualizing the volar extrinsic carpal ligament.



**Figure S2.** The position of the transducer for visualizing the volar intrinsic carpal ligament.



**Figure S3.** The position of the transducer for visualizing the dorsal extrinsic carpal ligament.



**Figure S4.** The position of the transducer for visualizing the dorsal intrinsic carpal ligament.